

**EFFICACY OF MINIMALLY INVASIVE TECHNOLOGY IN THE SURGICAL TREATMENT OF PANCREATIC CYSTS**

Полвонниёзов Хумоюн Гайратжон угли,
ассистент

Отамирзаев Кудрат Абдужаббор угли,
ассистент

Ортикбоев Фарход Дилшод угли
ассистент

ABSTRACT

The relevance of the treatment of pancreatic cysts (pancreas) is determined by an increase in the incidence of pancreatitis, a significant number of complications and high lethality. In recent decades, there has been a steady increase in destructive forms of pancreatitis, respectively, the number of pancreatic cysts increases. Pancreatic cysts in 18-68% cause various complications (suppuration, perforation, bleeding, internal and external fistulas, malignancy), which determines a high mortality rate of 9.2-53%. The nature and scope of surgical intervention depend on the etiology, the presence or absence of a cyst connection with the ductal system, the presence of complications.

The high prevalence of cystic lesions of the pancreas, the difficulties in choosing the optimal method of treatment require the creation of a rational, convenient for clinical practice diagnostic and therapeutic algorithm. Dissatisfaction with the results of treatment and a large number of complications prompt the search for a new, so-called gold standard for the treatment of patients and the definition of the real place of mini-invasive and open surgical methods.

Keywords: chronic pancreatitis, pancreas, pancreatic cyst, pseudocyst, mini-invasive surgery.

Introduction

The prevalence of CP over the past 5 years has increased by 3 times, while people of young and working age are more likely to get sick, which is the cause of disability of 15% of patients and leads to economic costs both in enterprises and in the country as a whole [2].

Pancreatic cysts in the process of formation and clinical course in 18–68% of cases cause various complications (suppuration, perforation, bleeding, internal and external fistulas, malignancy), which determines a high mortality rate of 9.2–53% [7, 12, 14].

At the present stage of treatment of patients with pancreatic cysts, there is a general tendency to introduce minimally invasive interventions into surgical practice. Endoscopic and percutaneous operations, which are performed under the control of modern tracking tools, have become widespread due to low invasiveness and relative safety [2, 3, 7, 13]. As a visual control



over the course of percutaneous punctures and drainage of the pancreas, echolocation [4, 7, 14] and CT [9, 11] are most often used, less often - X-ray television [10, 18, 20].

The introduction of mini-invasive technologies may in some cases be an alternative to traditional treatments [18,22]. A number of authors assess the results of percutaneous puncture-draining interventions as promising [1, 3, 6, 13, 19]. However, in the literature there is an opinion about the limited role of these interventions in the complex surgical treatment of PC [2, 5, 8, 15, 16], since it should not be forgotten that, despite the low invasiveness, 7–34.6% of patients may develop such severe complications as the formation of external pancreatic fistulas, bleeding into the lumen of the organ, septic reactions [7, 11, 17, 19]. Cases of deaths associated with sepsis, acute pancreatitis, myocardial infarction are described [1, 10, 11, 21].

Objective:

To develop selective tactics of surgical treatment of patients with cystic formations of the pancreas.

Materials and Methods

Surgical treatment was subject to 46 patients with pancreatic cysts who were in the surgery department in the 1st city hospital No. 1 of Tashkent in the period from 2011 to 2023. True cysts took place in 5 observations (10.87%), pseudocysts were noted in 41 patients (89.13%). The average age of patients was (49.6 ± 1.4) years. Punctures under sonological control were performed with Chiba needles (G18-22), when draining cysts, standard kits with pig tail drainage were used.

Outcomes

According to the timing of the formation of cysts, we distinguish a period of up to 2 months, characterized by the appearance of extrapancreatic liquid accumulations, up to 3-4 months - the period characteristic of the formation of a young cystic cavity, and a period of more than 4 months when a mature cystic cavity is formed.

The localization of cysts (extra- or intrapancreatic location), compression of neighboring organs (Fig. 1a) or distal parts of the pancreas, wall thickness, which made it possible to judge the maturity of cysts, were evaluated. At the same time, such an important characteristic for the choice of treatment tactics as a connection with the ductal system, according to ERCP, could be established only in 28.75% of observations (Fig. 1b).

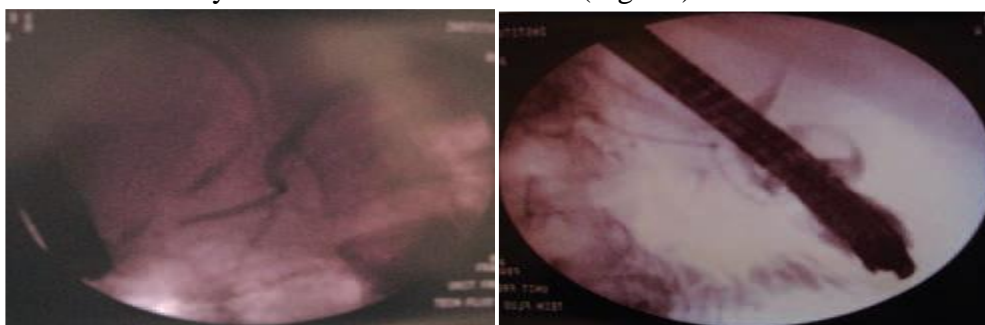


Figure 1 - ERCP: on the left (a) compression of the common bile duct by pseudocystic pancreas; right b) the connection of the pancreatic cyst with the main pancreatic duct



When imaging during the ERCP of the unchanged main pancreatic duct, puncture and aspiration of cysts were performed under sonological control, which, according to CT data, were in the projection of the head, body or tail of the pancreas (Fig. 2a, b). Next, an assessment of enzymatic activity and a cytological study of the contents of the cystic cavity were carried out. Low amylase activity and the absence of cellular atypia made it possible to limit ourselves to one or two aspirations. If the size of cystic formations was more than 6 cm, external drainage was performed under sonological control.

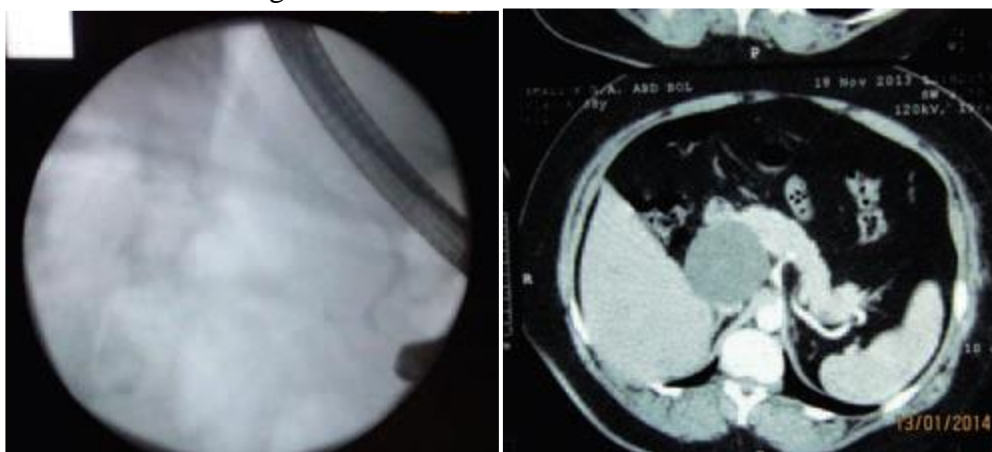


Figure 2 — left (a) ERCP, normal virsungogram; right b) cyst of the tail of the pancreas. With a normal virsungogram according to ERCP and the presence of cystic formation of the tail of the pancreas with the ineffectiveness of mini-invasive methods, distal resection of the pancreas was performed, while the absence of ductal hypertension made it possible to perform treatment of the proximal stump of the pancreas without pancreatodigestive junction (Fig. 3a, b).

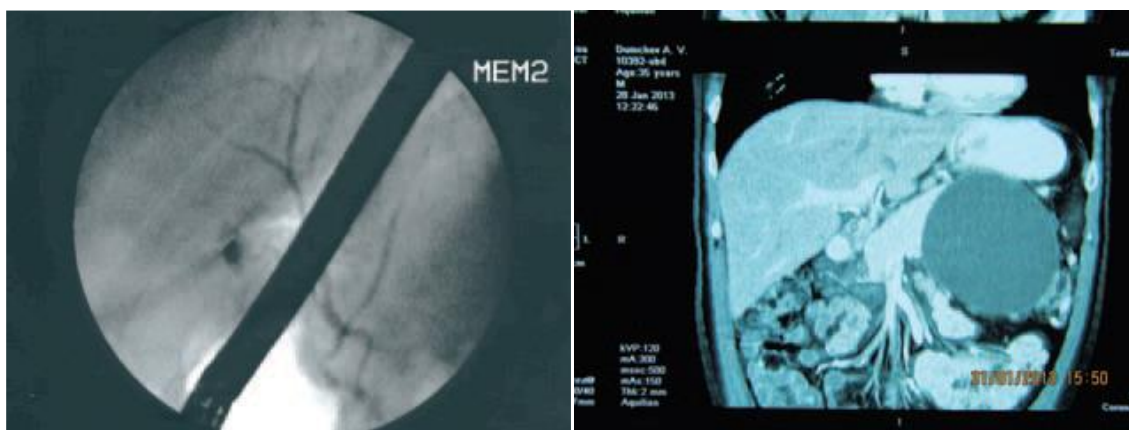


Figure 3 — left (a) ERBCG, normal virsungogram; right b) cyst of the tail of the pancreas. With the dilatation of the main pancreatic duct, the presence of cystic formation of the head of the pancreas, indications for internal drainage were exposed (Fig. 4a, b). We agree with the opinion of M.V. Danilov et al. (2011) that percutaneous drainage of pancreatic pseudocysts against the background of intrapancreatic hypertension is accompanied by the occurrence of cyst recurrence and the presence of long-existing pancreatic fistulas, which requires internal drainage [9].

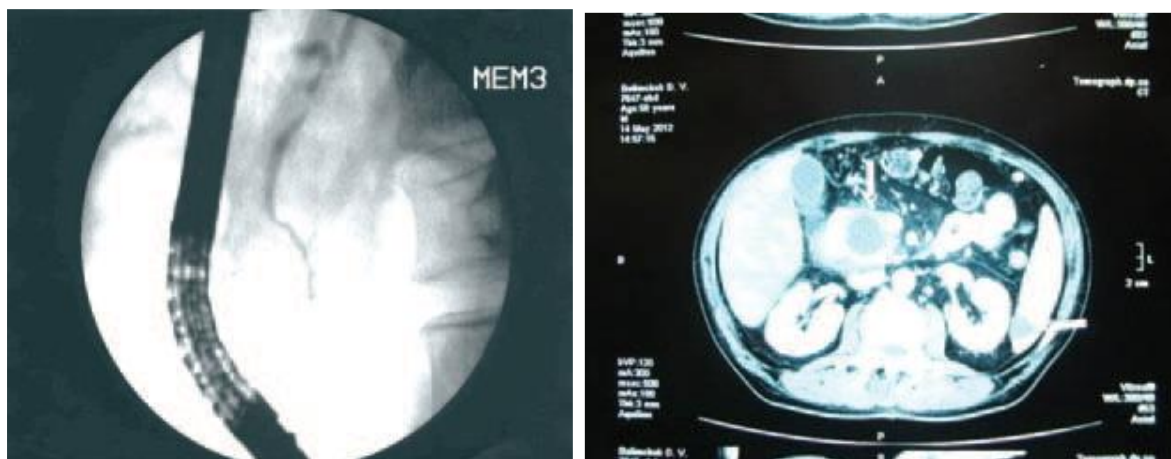


Figure 4 - on the left a) ERCP, virsungodilation with a segmental obstruction site in a patient with pseudocystic pancreas; on the right b) CT scan of the same patient with a cyst of the head of the pancreas

The nature of surgical interventions is displayed in Table. 1.

Table 1 — Nature of surgical interventions

Nature of surgery	Number of patients	
	N	%
Puncture, aspiration of a cyst, liquid accumulation under ultrasound control	7	15,2
External drainage of the cyst under ultrasound control	8	17,4
External drainage of the cyst under ultrasound control + distal resection of the pancreas, splenectomy	4	8,7
External drainage of the cyst under ultrasound control + cystoduodenostomy	4	8,7
Cystopancreatoeyenostomy	18	39,1
Operation Frey	5	10,9
Altogether	46	100

Complications occurred in 4 patients (8.7%): dislocation of drainage during external drainage of pseudocysts - 1, bleeding into the cyst cavity during external drainage under ultrasound control - 2, failure of sutures of pancreatic eyenoanastomosis - 1. There were no fatalities.

Thus, the above data indicate that patients with pancreatic cysts need an individual approach in choosing treatment tactics. The first choice in the complex therapy of this pathology is the use of mini-invasive puncture-draining technologies, which were an effective method of treatment in 32.8% of cases.

Analysis of the literature and own data obtained in the treatment of patients with pancreatic cysts indicates that the choice of the method of surgical treatment should be determined not only by the size, localization, number of cysts and their complications, but also by the nature of the complications of the gland itself in the form of acute or chronic inflammation, the presence of calcifications, the degree of pancreatic fibrosis and the state of the ductal system. Any surgical intervention should be aimed not only at eliminating the complication of the



disease - the cyst, but also at the cause of its occurrence, taking into account the violation of the outflow of pancreatic contents and intraductal hypertension.

References:

1. Therapeutic and tactical approaches in patients with pancreatic pseudocysts / V.V. Boyko, I.A. Krivoruchko, A.M. Tishchenko [et al.] // *Klinichna hirurgiya*. — 2004. — № 6. — S. 16-19.
2. Teshaeв, O. R., Rakhmonova, G. E., Jumaev, N. A., & Babadjanov, A. B. (2020). A REVIEW OF SPREADING WAYS, FEATURES OF DIAGNOSIS AND TREATMENT OF CORONAVIRUS INFECTION. *Central Asian Journal of Medicine*, 2020(3), 119-134.
3. Navruzov, B., Teshaeв, O., Kholov, Kh., Ubaidullaev, Z., & Ortikboev, F. (2023). INSUFFICIENCY OF THE SPHINCTER DURING SURGERY ON EXTRASPHINCTER FISTULAS (LITERATURE REVIEW). *Eurasian Journal of Medical and Natural Sciences*, 3(4), 55-67.
4. Teshaeв, O. R., Madaminov, R. M., Gafurov, B. T., Khudoyberganova, N. S., & Ismoilov, M. U. (2020). Surgical Treatment Of Acute Calculous Cholecystitis In Patients With Type 2 Diabetes Mellitus. *European Journal of Molecular and Clinical Medicine*, 7(8), 1296-1309.
5. Vasiliev A.A. Percutaneous drainage of acute postnecrotic cysts with destructive pancreatitis as an alternative to traditional surgical treatment / A.A. Vasilyev // *Universitetska klinika*. — 2007. — Vol. 3, No. 1. — S. 9-12.
6. Raimkulova, N. R., & Usmonbekova, G. U. (2017). Nephroprotective effect of statins in patients with chronic glomerulonephritis. *Young Scholar*, (8), 131-133.
7. Teshaeв, O. R., & Zhumaev, N. A. (2023). THE IMMEDIATE RESULTS OF SURGICAL TREATMENT OF OBESITY. *Eurasian Journal of Medical and Natural Sciences*, 3(2), 200-208.
8. Ismoilov, F. M. DIAGNOSTICS AND TREATMENT OF PATIENTS WITH ACUTE INTESTINAL OBSTRUCTION. *Zbiór artykułów naukowych recenzowanych.*, 69.
9. Teshaeв, O., Kholov, Kh., Babazonov, A., & Ortikboev, F. (2022). THE USE OF MESH IMPLANTS FOR DIAPHRAGMATIC HERNIA OF THE ESOPHAGEAL OPENING (LITERATURE REVIEW). *Eurasian Journal of Medical and Natural Sciences*, 2(6), 257-264.
10. Khayitov, I. B., Teshaeв, O. R., & Ortikboev, F. D. (2020). THE ROLE AND PLACE OF ALBENDAZOLE IN THE TREATMENT OF ECHINOCOCCOSIS OF THE LIVER.
11. Ergashev, U. Yu., Malikov, N. M., Ortikboev, F. D., & Minavarkhuzhaev, R. R. (2023). Peritoneal Mannheim index in the prediction of postoperative complications in patients with peritonitis.
12. Ergashev, U. Y., Abdusalomov, B. A., Minavarkhojayeв, R. R., Ortiqboyev, F. D., & Malikov, N. M. (2023). EVALUATION OF THE PATHOMORPHOLOGY OF REGENERATION IN DIABETIC FOOT SYNDROME AND DETERMINATION OF



- ITS DEPENDENCE ON BIOCHEMICAL PROCESSES. *World Bulletin of Public Health*, 19, 66-78.
13. Teshaeв, O. R., Ruziev, U. S., Tavasharov, B. N., & Zhumaev, N. A. (2020). Efficacy of bariatric and metabolic surgery in the treatment of obesity. *Medical News*, (6 (309)), 64-66.
 14. Danilov M.V. Repeated and reconstructive operations for pancreatic diseases / M.V. Danilov, V.D. Fedorov. — M.: Meditsina, 2003. — S. 238-273.
 15. Khaitov, I. B., & Jumaev, N. A. (2023). SIMULTANEOUS OPERATION: LIVER ECHINOCOCCOSIS AND SLEEVE RESECTION (CLINICAL CASE).
 16. Pancreatic pseudocysts in recurrent pancreatitis: traditional and minimally invasive surgery/endothrapy. Problems of choosing a treatment strategy / M.V. Danilov, V.P. Glabai, V.G. Zurabiani [et al.] // *Klinichna khirurgiya*. — 2011. — № 1. — S. 35-40.
 17. Agzamova, M. N., & Usmonbekova, G. U. (2018). Effectiveness of complex treatment of patients with acute peritonitis. *Young Scholar*, (18), 135-137.
 18. Mustafakulov, G. I., Mominov, A. T., & Ortikboev, F. D. (2023). An integrated approach to improving treatment outcomes for autoimmune thrombocytopenic purpura.
 19. Yusufjanovich, E. U. (2023). Management of Patients with Acute Arterial Ischemia of the Lower Limb. *International Journal of Scientific Trends*, 2(2), 43-48.
 20. Navruzov, B., Ubaidullaev, Z., Ortikboev, F., & Usmonov, B. (2023). IMPROVED RESULTS TREATMENT OF SPHINCTER INSUFFICIENCY AFTER SURGERY FOR EXTRO- AND TRANS SPHINCTER FISTULAS. *Eurasian Journal of Medical and Natural Sciences*, 3(3), 97-103.
 21. Teshaeв, O. R., Ruziev, U. S., Murodov, A. S., & Zhumaev, N. A. (2019). THE EFFECTIVENESS OF BARIATRIC AND METABOLIC SURGERY IN THE TREATMENT OF OBESITY. *Toshkent tibbiyot akademiyasi axborotnomasi*, (5), 132-138.
 22. Pancreatic pseudocysts: diagnosis and surgical treatment / Ya.G. Kolkin, V.V. Khatsko, S.O. Shatalov [and others] // *Sciences. herald Uzhgor. Univ., series "Medicine"*. — 2006. — Vol. 29. — P. 38-40.
 23. Dilmurodovich, A. D., Bahodirovich, G. Y., Dustqobilovich, A. K., & Uchqun o'g'li, B. S. (2021). Comparative Features of Breast Cancer in Patients with and Non-Suffering with Type 2 Diabetes Mellitus. *European Journal of Life Safety and Stability (2660-9630)*, 12, 68-70.
 24. Samigova, N. R., Sherkuzieva, G. F., Achilov, D. D., & Boboyorov, S. U. Ў. (2021). ASSESSMENT OF THE WORKING CONDITIONS OF CERAMIC TILE WORKERS. *Scientific progress*, 2(6), 1586-1591.
 25. Аллаева, М. Ж., Асқаров, О. О., & Кдырниязова, С. А. (2017). The study of hypoglycemic effect of dry extract of chicory. *Биология и интегративная медицина*, (3), 184-191.